

# Advances in Multimodality Therapy for Laryngeal Cancer

John F. Carew, MD

Jatin P. Shah, MD

## Introduction

Head and neck cancer is the sixth most common form of cancer worldwide.<sup>1</sup> More than 90% of head and neck cancers are squamous cell carcinomas. The oral cavity is the most common site within the head and neck, and the larynx is the second most common. The American Cancer Society projects 11,100 new cases of laryngeal cancer and 4,300 deaths from laryngeal cancer in the United States in 1998 (Figure).<sup>2</sup>

In the last two decades, the 5-year survival of patients with laryngeal cancer has not changed dramatically.<sup>2</sup> In a recent study of 16,213 patients with laryngeal cancer, overall 5-year disease-specific survival was 75%.<sup>3</sup> Of these patients, less than 40% presented with advanced disease (stage III or IV).<sup>3</sup>

In most patients with early stage disease (stage I or II), local control and survival are achieved with single-modality therapy consisting of either external beam radiation therapy or surgery.<sup>3,4</sup> Advanced-stage squamous cell carcinoma of the larynx, in contrast, requires multimodality therapy. Despite the use of multimodality treatment, survival for patients

with advanced-stage disease ranges from 42% to 77%.<sup>3,5,6-11</sup>

Until the early 1980s, multimodality therapy for advanced-stage laryngeal cancer consisted of surgery and external beam radiation therapy. In the early 1980s, however, several trials showed a high rate of tumor response to induction chemotherapy in patients with squamous cell carcinoma of the head and neck. Based on these trials, treatment paradigms evolved using induction chemotherapy followed by radiation therapy.<sup>12,13</sup> The goal of these strategies was to develop a treatment program for laryngeal cancer that preserved laryngeal function but did not adversely affect survival.

In the early 1990s, a prospective, randomized trial was conducted of patients with stage III or IV squamous cell carcinoma of the larynx treated at Veterans Affairs Hospitals.<sup>5</sup> Patients received either conventional treatment with surgery and postoperative radiation therapy or induction chemotherapy followed by radiation therapy. Patients in the chemotherapy-radiation therapy arm who did not have at least a 50% response to induction chemotherapy or who showed persistent or recurrent disease after radiation therapy were salvaged with surgery.

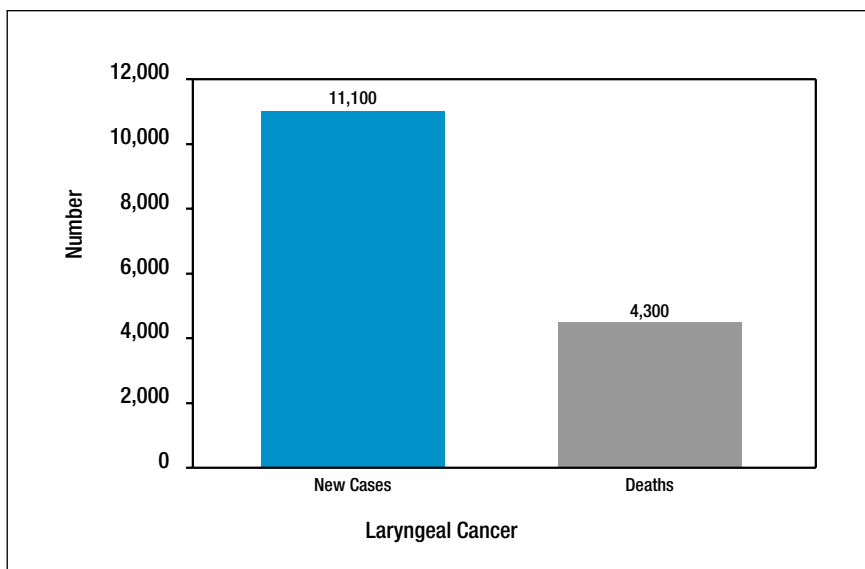
In this landmark study, differences in survival in the two treatment arms were not statistically significant (68% in each arm), and physicians were able to preserve the larynx in 64% of patients in the chemotherapy-radiation therapy arm.<sup>5</sup> A new option now existed for patients with advanced-stage laryngeal can-

---

Dr. Carew is Fellow, Head and Neck Service, Department of Surgery, Memorial Sloan-Kettering Cancer Center, New York, NY.

Dr. Shah is Chief, Head and Neck Service, and E.W. Strong Chair in Head and Neck Oncology, Department of Surgery, Memorial Sloan-Kettering Cancer Center; and Professor of Surgery, Cornell University Medical Center, New York, NY.

This article is also available online at <http://www.ca-journal.org>.



American Cancer Society's estimates of new cases of laryngeal cancer and deaths from laryngeal cancer in 1998 (data from Landis et al<sup>2</sup>).

cer. In this review, we discuss the advances in multimodality therapy of squamous cell carcinoma of the larynx that have evolved in the last 20 years.

### General Considerations

The larynx can be subdivided into glottic, supraglottic, and subglottic anatomic regions. Squamous cell carcinomas of the larynx occur most often in the glottic larynx (56%), next most often in the supraglottic larynx (31%), and rarely in the subglottis (1%).<sup>3</sup>

Tumors in these subsites have different clinical behaviors and risks of regional lymph node metastasis. Supraglottic tumors, for example, have a much higher rate of occult and bilateral regional lymph node metastases than do glottic primaries.<sup>14,15</sup> Rates of regional failure for patients with supraglottic primaries, as a result, are higher than those for patients with similarly staged glottic prima-

ry tumors.<sup>3</sup> Because of the high risk of regional dissemination, patients with supraglottic primaries have worse 5-year disease-free survival rates than do patients with glottic primaries.<sup>3</sup>

The stage of the disease also affects survival of patients with laryngeal cancer. Patients with stage I or II disease have 5-year disease-specific survival rates ranging from 78% to 91%, whereas those with stage III or IV have rates ranging from 42% to 67%.<sup>3</sup>

Presently, the American Joint Committee on Cancer (AJCC) staging system for laryngeal cancer depends on the local extent of the tumor (T stage) and the status of regional lymph nodes (N stage).<sup>16</sup> Although survival has been related to both T and N, it is most profoundly affected by the nodal status of the patient.<sup>3,14,17</sup> Patients with either early localized tumors (T1,2 N0) or advanced localized tumors (T3,4 N0) have 5-year disease-specific survival rates of 87.5%

and 72.1%, respectively.<sup>3</sup> In contrast, patients with regional lymph node metastasis, have a 5-year disease-specific survival of 46.2% for all T stages (T1-4 N >0).<sup>3</sup>

Regional lymph node involvement is known to decrease survival by approximately half.<sup>14,17</sup> The present AJCC staging system groups together into stage III both patients with locally advanced tumors (T3 N0) and patients with regional lymph node metastasis (T1-3 N1).<sup>16</sup> This may arbitrarily group together two subsets of patients who have widely different prognoses. Both the stage and the nodal status must be considered in the interpretation of results from the treatment of advanced-stage laryngeal cancer.

A critical element in the consideration of any trial involving patients with laryngeal cancers is the proportion of patients with supraglottic primaries, advanced-stage disease, or regional lymph node metastasis. In nonrandomized studies, a selection bias exists that affects which treatment is used for specific patient populations. Even in prospective randomized trials, clinical setting, referral patterns, and inclusion criteria bias the study with regard to which patients constitute the study population.

The treatment protocols proposed in these trials, therefore, must be applied with caution. Individual patient factors such as laryngeal subsite, stage, regional lymph node metastasis, comorbidities, and patient compliance, as well as the clinical environment in which the patient is treated, must be considered.

## Historical Review

Treatment of cancer of the larynx was initially limited by the inability of physicians to examine the larynx adequately. In the mid-1800s, a singing teacher named Manuel Garcia used a mirror to indirectly visualize his own vocal folds.<sup>18</sup> Later in the 1800s Kirstein performed the first direct visualization of the endolarynx by direct laryngoscopy.<sup>18</sup>

Tools used to visualize the interior of the larynx have evolved substantially over the past hundred years. Recently, the widespread use of the fiberoptic laryngoscope has allowed unparalleled visualization of the larynx in the outpatient setting. In the operating room, the use of 0°, 30°, and 70° telescopes has improved visualization of areas that previously had been difficult to examine, such as the subglottis.

Early attempts at curative treatment of laryngeal cancer, in the middle and late 1800s, were directed primarily at surgical approaches. The first surgical approach, performed in 1851, was a laryngofissure, in which the thyroid cartilage was split in the midline to gain access to the tumor.<sup>18</sup> In 1876, Billroth performed the first total laryngectomy; several years later he performed the first vertical partial laryngectomy.<sup>19</sup> Late in the nineteenth century, Solis-Cohen described diverting the tracheal remnant to the skin, and Sorensen reported a single-stage pharyngeal closure.<sup>18</sup>

Over the ensuing decades, the morbidity and mortality from these procedures decreased as experience increased. In the early twentieth century, Gluck reported 160 total laryngectomies, with no mortalities in the last 63 consecutive cases.<sup>20</sup>

Surgery remained the mainstay of treatment of laryngeal cancer until the 1920s, when Coutard advocated fractionated external beam radiation therapy as a definitive treatment modality.<sup>21</sup> The use of megavoltage radiation further improved results, and this modality was widely applied in the 1950s.

From this time onward, external beam radiation therapy has remained an effective form of definitive treatment of early-stage laryngeal cancer and an option for definitive or adjuvant treatment of advanced-stage laryngeal cancer. During most of the mid-twentieth century, external beam radiation therapy was the primary treatment modality

for laryngeal cancer.

Surgical approaches, however, resurged in the second half of the twentieth century. Much of this could be attributed to an improved understanding of the predictability of local growth and spread of laryngeal tumors as described by Kirchner in his whole-organ laryngeal sectioning studies.<sup>22</sup> This knowledge was applied in further refinements in partial laryngeal surgery as popularized by Alonso and Ogura.<sup>23-25</sup> In the latter half of the twentieth century, conservation laryngeal surgery reached its limits with the description of the near-total laryngectomy by Pearson<sup>26</sup> and the supracricoid subtotal laryngectomy by Laccourreye et al.<sup>27</sup>

Another approach to conservation surgery of the larynx evolved from Jako's popularization of the laser as a tool for laryngeal surgery.<sup>28</sup> The laser has allowed surgeons to resect lesions through the laryngoscope while maintaining hemostasis. Surgeons are now able to resect T2 and T3 laryngeal tumors through an endoscopic approach using the laser, as reported by Steiner and Zeitels et al.<sup>29,30</sup>

Over the last century, attempts to improve the ability to speak after treatment of laryngeal cancer have proceeded on two fronts. First, as mentioned earlier, surgical techniques have evolved that spare as much of the larynx as oncologically possible. Second, improved methods of voice rehabilitation after total laryngectomy have evolved. In the most significant of these, popularized by Blom and Singer,<sup>31</sup> a fistula is created between the trachea and the esophagus and a small duck-billed prosthesis is placed in the fistula. This procedure allows the patient to produce lung-powered speech that is often quite satisfactory.

Despite the many advances made in the treatment of laryngeal cancer over the last century, survival in patients with advanced cancer of the larynx has improved little in the last 25 years.<sup>2</sup>

## Goals of Treatment

Improving survival continues to be the ultimate goal in treating patients with advanced-stage laryngeal cancer. Recently, however, because of the lack of improvement in survival, significant efforts have been made to improve the quality of life in these patients. Paramount to this is preservation of a functional larynx.

Treatment options have been formulated with the hope of increasing laryngeal preservation without sacrificing survival. A small cohort of patients given the choice opt for treatments that may improve laryngeal preservation even if survival rates are not as good as those achieved with other techniques.<sup>18</sup> Multimodality therapy in the form of neoadjuvant chemotherapy, radiation therapy, and surgical salvage has emerged as a viable treatment option that allows anatomic preservation of the larynx without sacrificing survival.<sup>5</sup> Now that a method of laryngeal preservation has been established, future goals in treatment are to increase the rates of both laryngeal preservation and survival.

## Treatment Options

### OVERVIEW

In the past, conventional treatment of advanced-stage laryngeal cancer consisted of surgery and postoperative external beam radiation therapy. Surgical resection of most advanced-stage laryngeal lesions consisted of total laryngectomy with the resultant deleterious effects on deglutition and phonation and the creation of a permanent tracheostoma.

The psychosocial consequences of total laryngectomy have been well studied.<sup>32-35</sup> Not surprisingly, quality-of-life measurements and psychosocial indicators are significantly affected by total laryngectomy. Although techniques for voice rehabilitation have improved, studies have shown that the psychosocial effects of laryngectomy are related as much to loss of voice as they are to other fac-

tors, such as the need for a permanent tracheostoma.<sup>32-35</sup>

Appreciation of the psychosocial consequences of total laryngectomy has spurred the development of treatment options that could preserve the larynx of patients with advanced-stage laryngeal cancer. Initially, study of the anatomic barriers to and routes of tumor spread led to conservation surgical procedures in which tumors are resected en bloc while the function of the larynx is preserved. In selected patients, conservation surgical procedures can be used for advanced-stage tumors, often in combination with adjuvant radiation therapy to improve locoregional control.

Conservation surgical procedures continue to evolve and in combination with postoperative radiation therapy remain an effective form of multimodality treatment for selected patients with advanced-stage laryngeal cancer. Many patients, however, are not suitable candidates for conservation laryngeal procedures because of either oncologic concerns or patient factors such as inadequate pulmonary reserve.

#### INDUCTION CHEMOTHERAPY AND RADIATION THERAPY

Other modalities have evolved for treatment of patients with laryngeal cancer who are not candidates for conservation surgical procedures. With the results of the Veterans Affairs Laryngeal Cancer Study Group (VALCSG) trial, the combination of induction chemotherapy and radiation therapy has emerged as a treatment option that preserves the larynx in nearly two-thirds of patients.<sup>5</sup> Despite the convincing results of this prospective randomized trial, many controversies exist about it and its application to all patients with advanced-stage laryngeal cancer.

Table 1 summarizes results of several studies evaluating multimodality therapy in the treatment of patients with advanced-stage laryngeal cancer with the goal of preserving the larynx.<sup>5-11,36</sup> In

all but one study, more than 90% of patients evaluated had stage III or IV disease. Most studies included only patients who would have required a total laryngectomy if treated by conventional means (i.e., surgery and postoperative radiation therapy).

The incidence of regional lymph node involvement in the studies varied widely, from 28% to 83%. Treatment results for patients treated with chemotherapy and radiation therapy in the various studies are consistent, with 2-year survival rates ranging from 50% to 77%, larynx preservation rates ranging from 64% to 79%, locoregional failure rates ranging from 20% to 33%, and distant failure rates ranging from 8% to 21%.<sup>5-10,36</sup>

Only one of these studies, however, was limited only to patients with laryngeal primaries.<sup>5</sup> The other studies all included patients with the hypopharynx, oropharynx, oral cavity, and even paranasal sinuses as sites of primaries.<sup>6-11</sup> Most of the studies including nonlaryngeal sites did so because surgical treatment of the primary would have required total laryngectomy. The data in Table 1 refer to the subset of patients with laryngeal primaries whenever possible, although this information was not always available.

In two of the studies summarized in Table 1 comparisons were made between conventional treatment (surgery and postoperative radiation therapy) and treatment with induction chemotherapy and radiation therapy.<sup>5,11</sup> The VALCSG study was a randomized prospective trial, whereas the M.D. Anderson study was a matched-pair analysis. Neither showed a statistically significant difference in survival in the chemotherapy-radiation therapy arm compared with the conventional treatment arm.

Two interesting observations were made, however, that did have statistical significance. First, in both studies, locoregional control was improved in patients who received conventional therapy.<sup>5,11</sup>

**Table 1**  
**Results of Studies Evaluating Multimodality Treatment**  
**for Advanced Laryngeal Cancer**

Author	Y	N	Treatment	Stage III (%)	Stage IV (%)	Supra-glottic (%)	N1-3 (%)	CR+PR	2-Y Survival*	Lx preserved (%)	LR Failure (%)	Distant Failure (%)	Sites in Study
Jacobs et al <sup>6</sup>	1987	30	C/RT	37	63	—	83	90	52	—	33	20	Lx, HP, OC, OP
Demard et al <sup>7</sup>	1990	50	C/RT	54	10	—	28	74	—	—	—	—	Lx, HP†
Veterans Affairs Laryngeal Cancer Study Group (VALCSG) <sup>5</sup>	1991	166	C/RT	56	44	63	48	85	68	64	20	11‡	—
	1991	166	S/RT	57	43	62	43	—	68	—	7‡	17	—
Pfister et al <sup>8</sup>	1991	13	C/RT	43	55	77	63	85	77	68	31	8	Lx, HP, OP†
Karp et al <sup>9</sup>	1991	14	C/RT	21	71	—	50	71	50	79	21	21	Lx, HP†
Urba et al <sup>10</sup>	1994	8	C/RT	36	57	—	74	84	75	75	—	—	Lx, HP, OC, OP, sinus†
Clayman et al <sup>11§</sup>	1995	26	C/RT	68	28	65	—	75	68	65	—	—	Lx, HP†
		52	S/RT	—	—	65	—	—	81	—	—	—	—

\*Data are for disease-specific survival when this information was available; otherwise data are for overall survival.

†Study included both larynx and other sites; but statistics refer to patients with laryngeal primaries.

‡Statistically significant improvement ( $P < 0.05$ ) over other arm of study.

§Includes data from earlier study of the same patients by Shirinian et al.<sup>36</sup>

— = Data not available.

CR+PR = percentage of patients experiencing a complete or partial response (more than 50% reduction in tumor volume after induction chemotherapy); C/RT = induction chemotherapy (most commonly cisplatin and 5-fluorouracil) followed by radiation therapy with surgery reserved for salvage; HP = hypopharynx; LR = locoregional; Lx = larynx; N= number of patients in study with larynx as the site of primary cancer; OC = oral cavity; OP = oropharynx; S/RT = surgery followed by radiation therapy; Y = year.

Second, a decrease in the rate of distant metastasis was seen in the chemotherapy–radiation therapy arm in the VALCSG study. The latter may represent a delay in the presentation of the distant metastasis. Some investigators claim that this difference in rate of distant metastasis is not durable and equilibrates with time.<sup>37,38</sup> Although the significance of these differences in locoregional failure and distant failure have been debated, neither has translated into a survival advantage in either group.

These trials provide convincing evidence that induction chemotherapy followed by radiation therapy is an acceptable treatment option in patients with advanced laryngeal cancers that otherwise would have required a total laryngectomy. Critical analysis of these data, however, requires consideration of the results of conventional treatment with surgery and radiation therapy.

The results of the largest and most recent studies of conventional treatment are listed in Table 2.<sup>14,17,39-43</sup> In several of these studies, single-modality therapy in the form of definitive radiation therapy yielded disease-specific survival rates similar to those seen with the combination of induction chemotherapy and radiation therapy. Although these studies include fewer stage IV and node-positive patients than do the studies of chemotherapy and radiation therapy, the contribution of chemotherapy to these laryngeal preservation protocols remains undetermined. Previous randomized prospective trials did not include a radiation therapy–only arm; however, an ongoing intergroup trial has included a radiation therapy–only arm to address this question.

Two recently published studies compare radiation therapy alone with concurrent chemotherapy (cisplatin and 5-fluorouracil [5-FU]) and radiation therapy in patients with locoregionally advanced squamous cell carcinoma of the head and neck.<sup>44,45</sup> In these studies, between 36% and 56% of patients had either laryngeal

or hypopharyngeal primaries. In both studies, a statistically significant increase in 3-year relapse-free survival was seen in the concurrent chemotherapy–radiation therapy arm compared with the radiation therapy–alone arm ( $P < 0.0044$  and  $P < 0.0345$ ).

#### MORBIDITY

Currently, cisplatin with 5-FU is the most common chemotherapeutic combination used in these protocols.<sup>5,7,9-11,36</sup> Cisplatin is used in combination with bleomycin less often.<sup>8,9,36</sup> The pulmonary toxicity associated with bleomycin makes it a difficult agent to use in patients with squamous cell carcinoma of the larynx, who have a significant incidence of tobacco-related lung disease.

The VALCSG trial had several exclusion criteria as a result of the toxicity of the chemotherapy. These included performance status less than 50 on the Karnofsky scale; creatinine clearance less than 1 ml/second; white blood cell count less than 4,000/ml; platelet count less than 100,000/ml; and inadequate auditory, nutritional, pulmonary, or cardiac status. Because head and neck cancer patients have a high incidence of comorbidities, these criteria can exclude a significant number of patients.

Toxicity from induction chemotherapy also has prevented 7% to 18% of patients from receiving a full course of chemotherapy.<sup>5,6,8,10</sup> Even mortality as a direct result of induction chemotherapy toxicity has been reported to range from 0.6% to 6%.<sup>5,7-11,36</sup>

In addition to toxicity, the use of induction chemotherapy in combination with radiation therapy results in a complicated protocol with which it is difficult for patients to comply. The association of tobacco and alcohol use with squamous cell carcinoma of the larynx contributes to the poor compliance in these patients. In one study, protocol violations occurred in 12 of 40 patients because of toxicity or patient noncompliance.<sup>8</sup> Finally, a small percentage of patients responding favor-

**Table 2**  
**Results of Studies Evaluating Conventional Treatment**  
**of Advanced Laryngeal Cancer**

Author	Y	N	Treatment	Stage III (%)	Stage IV (%)	Supraglottic (%)	N1-3 (%)	Survival*	LR Failure
Kirchner & Owen <sup>39†</sup>	1977	308	S/RT	All T3 or T4	All T3 or T4	—	—	54-56 <sup>‡</sup>	—
Harwood et al <sup>40</sup>	1979	353	RT	32	22	0	13	70 <sup>§</sup>	—
Harwood et al <sup>41</sup>	1983	410	RT	18	48	100	35	57 <sup>‡</sup>	20
Yuen et al <sup>43</sup>	1984	192	S	79	21	—	18	77 <sup>‡</sup>	21
		50	S/RT	52	48	—	32	91 <sup>‡</sup>	8
Mendenhall et al <sup>42</sup>	1992	100	RT	94	6	0	25	74 <sup>‡</sup>	19
		65	S +/- RT	89	11	0	25	63 <sup>‡</sup>	19
Nguyen et al <sup>17</sup>	1996	116	S/RT	63	37	51	51	68 <sup>‡</sup>	23 <sup>**</sup>
Meyers & Alvi <sup>14</sup>	1996	65	S +/- RT	58	42	100	—	62 <sup>¶</sup>	—

\*Data are for disease-specific survival when this information was available; otherwise data are for overall survival.

<sup>†</sup>Study included larynx and other sites, but statistics refer to patients with laryngeal primaries.

<sup>‡</sup>Five-year survival.

<sup>§</sup>Weighted mean survival.

\*\*Distant failure rate was 13%.

<sup>¶</sup>Two-year survival.

— = Data not available.

LR = locoregional; N= number of patients in study with larynx as the site of primary cancer; S = surgery alone; S/RT = surgery followed by radiation therapy; S +/- RT = surgery with or without radiation therapy; RT = radiation therapy alone; Y = year.

ably to chemotherapy refuse further treatment, not understanding the lack of durability of their response.

In addition to the difficulties with patient compliance, the complexities of the chemotherapy–radiation therapy protocols make them difficult to transfer from the tertiary referral centers where they were developed to the community. Extensive cooperation among the head and neck surgeon, the radiation oncologist, and the medical oncologist is essential to maintaining the current rates of larynx preservation and survival.

Detecting patients who fail to respond to induction chemotherapy or who display persistent or recurrent disease after radiation therapy is critical to successful early surgical salvage. Often the posttreatment changes seen in the mucosa of the upper aerodigestive tract hamper the detection of persistent or recurrent disease.

#### SALVAGE

Once persistent or recurrent disease has been identified, early surgical salvage is the only curative option. The mucosa and tissues of the neck undergo changes after chemotherapy–radiation therapy. These not only make detection of recurrence difficult but also can make clinical assessment of the extent of locoregional disease challenging.

Many factors have been evaluated for their ability to predict local failure and the need for salvage laryngectomy. The VALCSG study found two patient groups with a statistically significant increased risk for local persistence or recurrence—those with T4 primary lesions and those with stage IV disease.<sup>5</sup> Survival was not affected by failure to respond to induction chemotherapy in this study.<sup>5</sup>

Salvage laryngectomy may be required for patients who fail to respond to induction chemotherapy and for those with persistent or recurrent disease after completing chemotherapy–radiation therapy. Approximately equal numbers of pa-

tients were found in these two groups in a recent study.<sup>46</sup> Most patients who require salvage laryngectomy because of persistent or recurrent disease after chemotherapy–radiation therapy manifest the disease within 1 to 2 years of completion of radiation therapy.<sup>5,46</sup>

Reports of 2-year disease-specific survival after salvage laryngectomy range from 56% to 80%.<sup>5,11,46</sup> Major complications after salvage laryngectomy, however, occur in nearly 50% of patients.<sup>46,47</sup> The most common complication is pharyngocutaneous fistula, which occurs at a rate of 27% to 50% in this cohort.<sup>46-48</sup> Wound complications and pharyngocutaneous fistula remain significant problems in salvage laryngectomy.

Survival after salvage neck dissection is worse than that after salvage laryngectomy. In the VALCSG study, of 24 patients who underwent salvage neck dissection, only 9 survived.<sup>49</sup> Treatment of the neck in the context of multimodality treatment of the larynx thus remains controversial.<sup>49,50</sup>

In the VALCSG trial, patients were evaluated after the second cycle of chemotherapy. If a major response of the primary tumor occurred and no evidence of disease progression in the neck was present, patients went on to receive definitive radiation therapy. After completion of radiation therapy, persistent or recurrent disease in the neck was salvaged with neck dissection. Of the 46 patients with N2 or N3 neck disease, 39% achieved a complete response in the neck with induction chemotherapy. Of the patients experiencing a complete response in the neck, 28% subsequently required salvage neck dissection.<sup>49</sup>

In the study by Armstrong and colleagues,<sup>50</sup> the response of the primary tumor and the spread of disease in the neck also were evaluated after induction chemotherapy. Patients who had a major response in the neck were treated either with neck dissection followed by radiation therapy or with radiation

therapy alone. Most patients with advanced N2c or N3 neck disease underwent neck dissection, and all patients with N1 neck disease were treated solely with radiation therapy. Of the patients experiencing a major response to induction chemotherapy, only 23% failed in the neck and required salvage neck dissection.<sup>50</sup> The optimal treatment of the neck and the possible identification of patients who do not require neck dissection await further study.

A recent report encompassing 9,334 patients with laryngeal cancer treated in the United States between 1990 and 1992 noted that only 8.2% of patients with stage III laryngeal cancer and 11% of those with stage IV were treated with the combination of chemotherapy and radiation therapy.<sup>3</sup> Although, these patients were treated during the time that the VALCSG report was published, it illustrates the point that as recently as 5 years ago, only approximately 10% of patients with advanced-stage laryngeal cancer were treated with chemotherapy–radiation therapy.

At our institution, most patients with advanced-stage laryngeal cancer who would require total laryngectomy if treated surgically are currently being treated with a larynx-preservation protocol of chemotherapy and radiation therapy. Current studies in the multimodality treatment of laryngeal cancer include evaluations of the benefit and role of chemotherapy in chemotherapy–radiation therapy protocols, patient selection, and biological markers predicting survival. Efforts to improve survival via innovative regimens, delivery systems, and novel therapeutic modalities are ongoing.

## Advances

### TREATMENT PARADIGMS

The most significant recent advances in the multimodality treatment of advanced-stage laryngeal cancer are seen in trials that investigate optimizing the de-

livery of radiation therapy and chemotherapy. Results of these studies are summarized in Table 3.

Higher rates of locoregional failure with chemotherapy–radiation therapy strategies have led to alterations in the timing and scheduling of radiation therapy. Protocols with accelerated fractionation of radiation therapy and plans using concomitant chemotherapy and radiation therapy have been investigated.

Researchers theorize that the increased locoregional failures seen with chemotherapy–radiation therapy protocols result in part from an accelerated tumor cell repopulation during the prolonged course of treatment.<sup>51,52</sup> Clinical and experimental evidence suggests that tumor cell populations, after a lag period of several weeks, decrease their doubling time and increase their rate of regrowth after cytotoxic treatment begins, no matter whether it is chemotherapy or radiation therapy.<sup>51,52</sup> A longer treatment time therefore results in high rates of failure.<sup>53</sup>

To combat these problems in chemotherapy–radiation therapy regimens, investigators have evaluated accelerated radiation therapy regimens and concomitant chemotherapy–radiation therapy protocols. In the past, accelerated (twice a day) courses of radiation therapy have improved 3-year local control of advanced laryngeal tumors (T3-4) from 26% to 59% ( $P < 0.0001$ ).<sup>54</sup>

These gains in local control are not without a cost in terms of treatment-related morbidity, however. In a study by Eisbruch et al,<sup>55</sup> grade 2 or 3 mucositis was seen in all patients, and 60% experienced late complications of radiation therapy. Of the 20 patients treated with chemotherapy and accelerated-fraction radiation therapy in this study, two required long-term tracheostomy and two required a long-term percutaneous gastrostomy tube. Although the larynx was anatomically preserved, its function was profoundly impaired in a subset of patients. Significant long-term treatment-re-

**Table 3**  
**Results of Studies Evaluating Treatment of Advanced Laryngeal Cancer**  
**with Sequential or Concomitant Chemotherapy and Radiation Therapy**

Author	Y	N	Treatment	Stage III (%)	Stage IV (%)	Supraglottic (%)	N1-3 (%)	CR+PR	2-Y Survival*	Lx Preserved	LR failure	Distant Failure	Comments
Eisbruch et al <sup>55</sup>	1996	33	C/RT	61	39	55	39	92	—	48	25	—	Accelerated fractionated RT
Robbins et al <sup>64</sup>	1996	42	C/RT†	14	86	69	79	95	76	90	14	7	Study sites: Lx, HP, OP
Pfister et al <sup>58</sup>	1994	62	CC/RT	—	66	—	—	63	—	72	—	—	Study sites: Lx, HP, OP
Pfister et al <sup>59</sup>	1993	61	C/RT	—	19	—	—	—	50	—	16	5	Study sites: Lx, HP, OP; chemotherapy: cisplatin & 5-FU
		62	C/RT	—	19	—	—	—	59	—	18	5	Study sites: Lx, HP, OP; chemotherapy: cisplatin & vinblastine or bleomycin

\*Data are for disease-specific survival when this information was available; otherwise data are for overall survival.

†This trial used a unique combination of high-dose intraarterial chemotherapy combined with conventional external beam radiation therapy.

— = Data not available.

CC/RT = concomitant chemotherapy and radiation therapy; CR+PR= percentage of patients experiencing a complete or partial response (more than 50% reduction in tumor volume after induction chemotherapy); C/RT = induction chemotherapy (most commonly cisplatin and 5-fluorouracil) followed by radiation therapy; 5-FU = 5-fluorouracil; HP = hypopharynx; Lx = larynx; N= number of patients in study with larynx as the site of primary cancer; OP = oropharynx; RT = radiation therapy; Y = year.

lated morbidity was seen in 25% of patients, which is more than the 5% to 11% rates seen in nonaccelerated protocols.<sup>5,8</sup> Additionally, all patients in this series undergoing salvage surgery after radiation therapy had major wound complications.<sup>55</sup> Ultimately, a benefit in local or regional control or survival was not seen in this study, although the study size was relatively small.<sup>55</sup>

Another method of shortening treatment time, decreasing the effects of accelerated tumor cell repopulation, and improving results involves the use of concomitant chemotherapy and radiation therapy. Previous studies using concomitant chemotherapy and radiation therapy in advanced-stage head and neck cancer have shown promising results with regard to locoregional control, organ preservation, and survival.<sup>56,57</sup> Prospective randomized trials assessing the benefit of concomitant chemotherapy and radiation therapy for advanced-stage laryngeal cancer have not been done, however.

In a study by Pfister et al<sup>58</sup> evaluating cisplatin-based chemotherapy with concomitant radiation therapy, less than 50% of patients enrolled were able to receive the planned treatment. Significant chemotherapy-related toxicity combined with a 37% nonresponse rate limited this study's ability to detect an advantage to concomitant therapy.

At this time, neither accelerated-fraction radiation therapy nor concomitant chemotherapy–radiation therapy has conclusively proved more beneficial than induction chemotherapy followed by conventional-fraction radiation therapy in treating advanced-stage laryngeal cancer. For this reason, along with the potential for treatment-related morbidity, accelerated-fraction radiation therapy remains investigational.

The Radiation Therapy Oncology Group is conducting a phase III trial comparing the following three treatment arms: (1) radiation therapy alone, (2) induction chemotherapy and radiation

therapy, and (3) concomitant chemotherapy and radiation therapy. This trial may help to define the role of concomitant therapy and the efficacy of radiation therapy without induction chemotherapy in advanced-stage laryngeal cancer.

The chemotherapy regimen most commonly used to treat advanced-stage laryngeal cancer is the combination of cisplatin and 5-FU. Several studies have evaluated the chemotherapeutic agents used in larynx-preservation protocols. Pfister et al performed a matched-pair analysis comparing cisplatin/5-FU, cisplatin/vinblastine, and cisplatin/bleomycin (Table 3).<sup>59</sup> Survival and locoregional control were statistically equivalent among the groups.

Another study investigated the benefit of adding leucovorin to cisplatin and 5-FU and found a 59% major response rate, but significant toxic effects were noted.<sup>60</sup> Two other studies evaluating the combination of cisplatin, 5-FU, and leucovorin showed overall response rates of 81% in patients with stage III and stage IV squamous cell carcinoma of the head and neck.<sup>61,62</sup> Finally, new chemotherapeutic agents continue to be developed. One such agent, paclitaxel, has yielded overall response rates of 58% when used in combination with cisplatin and ifosfamide in patients with recurrent head and neck squamous cell carcinoma.<sup>63</sup> Future studies should help to define the optimal chemotherapeutic regimen for larynx-preserving protocols.

Robbins et al<sup>64</sup> proposed a unique strategy using high-dose intraarterial cisplatin with a systemic neutralizing agent along with conventional radiation therapy. Results are promising (Table 3). Although most patients in this study had stage IV disease (86%) and clinically involved regional lymph nodes (79%), a major response rate was seen in 95% of patients. Nine of ten patients retained their larynx; 2-year disease-specific survival was 76%, and locoregional disease control was achieved in 86% of patients.

Three of the 42 patients, however, had central nervous system complications as a result of catheterization of the carotid system. Nevertheless, this remains a promising option and a novel approach in the treatment of advanced laryngeal cancer.

#### BIOLOGICAL MARKERS

Other advances in the treatment of laryngeal cancer have involved the use of molecular biological techniques to characterize biological markers that may predict which patients will be resistant to treatment. If a marker that would identify nonresponders could be defined, more aggressive treatment approaches or earlier surgical salvage could be instituted to improve survival in this cohort. Factors evaluated as potential biological markers predicting tumor response include adjusted DNA index, S-phase fraction labeling, potential doubling time, p53 overexpression, and p105 labeling.<sup>65-71</sup>

An increase in the adjusted DNA index has been correlated with an increase in complete response to induction chemotherapy.<sup>69</sup> In one study, all patients with a complete response to chemotherapy had an adjusted DNA index greater than 0.024, whereas 37% of patients having either a partial response or no response had an index lower than 0.024. Another study showed a higher rate of larynx preservation in patients with tumors overexpressing p53.<sup>68</sup> Finally, patients with aneuploid tumors have shown higher rates of complete response to induction chemotherapy than have those with diploid tumors.<sup>70</sup>

Studies by Robbins and colleagues<sup>72</sup> have shown a correlation between *in vitro* sensitivities to chemotherapeutic agents as determined by histoculture drug sensitivity assay and patient response to chemotherapy. This assay may provide a model for predicting which patients may respond favorably to chemotherapy. Further study is needed to assess the reliability of all the tests mentioned earlier in identifying patients

who will be nonresponders and the ability to translate this information into improved survival.<sup>65-68</sup>

Pretreatment measurements of potential doubling time have been used to determine which patients will benefit from accelerated-fraction radiation therapy.<sup>67</sup> In patients with a potential doubling time of 5 days or less, conventional radiation therapy yielded local control rates of 8% and accelerated-fraction radiation therapy resulted in control rates of 41% ( $P < .02$ ).<sup>67</sup> Other studies have shown trends toward a decrease in local control with longer treatment regimens in patients whose tumors display rapid cell division.<sup>73</sup>

Patients with advanced-stage laryngeal cancer who have short potential doubling times may benefit from shorter treatment plans in the form of either accelerated-fraction radiation therapy or concomitant chemotherapy-radiation therapy. Whether this pretreatment selection would affect locoregional control and, more importantly, survival awaits further evaluation.

#### Cost Analysis

An interesting analysis of the relative costs of the various treatment options for advanced-stage laryngeal cancer was presented at the Fourth International Conference on Head and Neck Cancer.

A model was created in which 100 hypothetical patients with T3N0 laryngeal tumors were treated by various protocols. Historical control rates were used to calculate the percentage of patients who required surgical salvage after treatment failed.<sup>74</sup> The treatment options included (1) primary radiation therapy with surgical salvage, (2) conventional surgery and postoperative radiation therapy, and (3) induction chemotherapy, radiation therapy, and surgical salvage.

The cost for the group that received primary radiation therapy with surgical salvage was \$4.2 million; for the group

treated with conventional surgery and postoperative radiation therapy, it was \$6.2 million; and for the group that received induction chemotherapy, radiation therapy, and surgical salvage it was \$6.4 million.<sup>74</sup> This analysis focused on direct costs and did not consider indirect costs related to morbidity, mortality, and lost income. In previous analysis, indirect costs have usually accounted for two-thirds of the total cost.<sup>74</sup> Factors other than cost, which are difficult to factor into this equation, such as quality of life, also must be considered. Although the cost of treatment options is an interesting consideration, the optimal treatment of patients with laryngeal cancer remains the primary concern.

### Extralaryngeal Sites

With the encouraging results from the various trials using the combination of induction chemotherapy and radiation therapy for advanced laryngeal cancer, similar trials have been applied to other sites that would require total laryngectomy if treated conventionally.

The most commonly studied site is the hypopharynx. Results of these studies are summarized in Table 4.<sup>75-79</sup> Hypopharyngeal tumors (most often involving the pyriform sinus) have shown lower rates of larynx preservation (29% to 52%), locoregional control (39% to 69%), and survival (19% to 42%) compared with laryngeal primaries.<sup>75-79</sup> In the largest randomized prospective trial, Lefebvre et al<sup>75</sup> reported equal survivals in the conventional surgery–radiation therapy arm and the induction chemotherapy–radiation therapy arm. These results have been corroborated by results from retrospective studies.<sup>77,79</sup>

A recent study by Beauvillain et al,<sup>76</sup> however, showed an improved 5-year survival in patients receiving induction chemotherapy, surgical resection, and postoperative radiation therapy (37%) compared with patients receiving induc-

tion chemotherapy and radiation therapy (19%). However, the patients who did not respond to induction chemotherapy went on to definitive radiation therapy rather than opting for early surgical salvage as in the VALCSG trial.<sup>76</sup> Controversy continues regarding the optimal treatment of hypopharyngeal cancer, and improvements in locoregional control and survival are needed.

Although chemotherapy–radiation therapy protocols have defined their role in the treatment of advanced-stage laryngeal cancer, conservation surgery that preserves the function of the larynx remains an excellent treatment option in selected patients. Recently, supracricoid partial laryngectomy with either cricohyoidopexy or cricohyoidoepiglottopexy has extended surgeons' ability to resect advanced laryngeal lesions with acceptable functional outcome and survival.<sup>27</sup>

Overall, treatment protocols using chemotherapy–radiation therapy to preserve organ function have successfully shown their ability to preserve the larynx anatomically without compromising survival. One aspect of these protocols that is often underappreciated, however, is the functional capacity of the retained organs. Few investigators have clearly documented the functional sequelae of chemotherapy and radiation therapy.

In a retrospective study of patients being treated with chemotherapy and radiation therapy Lazarus et al<sup>80</sup> found that 40% had swallowing difficulties. Clinical evidence of disorders in the pharyngeal phase of swallowing has been shown in patients who have undergone chemotherapy and radiation therapy for tumors of the upper aerodigestive tract. Reduced laryngeal closure, reduced laryngeal elevation, and reduced posterior tongue base movement relative to age-matched controls have been documented.<sup>80</sup>

Certainly, patients who successfully undergo chemotherapy–radiation therapy treatments to preserve the larynx have a much improved quality of life com-

**Table 4**  
**Results of Studies Evaluating Chemotherapy and Radiation Therapy or**  
**Surgery and Radiation Therapy for Treatment of Advanced Hypopharyngeal Cancer**

Author	Y	N	Treatment	Stage III [%]	Stage IV [%]	N1-3[%]	CR+PR	2- or 3-Y Survival[%]*	5-Y Survival[%]*	Lx Preserved[%]	LR Failure[%]	Distant Failure[%]
Kraus et al <sup>77</sup>	1994	25	C/RT	20	76	72	52	32	—	32	52	24
Lefebvre et al <sup>75</sup>	1996	100	C/RT	59	34	64	86	43	25	35	40	25 <sup>†</sup>
		94	S/RT	54	39	63	—	32	27	—	31	36
Zelesky et al <sup>79</sup>	1996	26	C/RT	27	65	60	81	—	30	52	—	23
		30	S/RT	40	60	93	—	—	42	—	—	40
Beauvillain et al <sup>76</sup>	1997	45	C/RT	—	—	67	79	—	19	38	61	—
		47	C/S/RT	—	—	70	67	—	37 <sup>‡</sup>	—	37	—
Kraus et al <sup>78</sup>	1997	132	S/RT <sup>‡</sup>	36	42	59	—	—	41	29	39	12

\*Data are for disease-specific survival when this information was available; otherwise data are for overall survival.

<sup>†</sup>Statistically significant improvement ( $P < 0.05$ ) over other arm of study.

<sup>‡</sup>In this trial, 80% of patients received postoperative radiation therapy.

— = Data not available.

CR+PR: percentage of patients experiencing a complete or partial response (more than 50% reduction in tumor volume after induction chemotherapy); C/RT: induction chemotherapy (usually cisplatin and 5-fluorouracil) followed by radiation therapy with surgery for salvage; C/S/RT: unique combination of induction chemotherapy followed by surgery followed by radiation therapy; LR = locoregional; Lx = larynx; N= number of patients in study with larynx as the site of primary cancer; S/RT: surgery followed by radiation therapy; Y = year.

pared with patients requiring total laryngectomy. Nevertheless, it should be realized that anatomic preservation does not always result in functional preservation.

## Conclusion

The combination of induction chemotherapy with external beam radiation therapy has been established as an effective means of treating selected patients with advanced-stage laryngeal cancer.

The cooperation of the head and neck surgeon, radiation oncologist, and medical oncologist is paramount to the successful use of this treatment. Investigations continue to evaluate the ideal treatment regimen, the delivery of chemotherapy, patient selection, biological markers predicting response, functional outcome, and the effectiveness of this treatment at other sites. The goal, however, remains to improve survival in patients with advanced-stage disease. **CA**

## References

- Vokes EE, Weichselbaum RR, Lippman SM, et al: Head and neck cancer. *N Engl J Med* 1993;328:184-194.
- Landis SH, Murray T, Bolden S, et al: Cancer statistics, 1998. *CA Cancer J Clin* 1998;48:6-29.
- Shah JP, Karnell LH, Hoffman HT, et al: Patterns of care for cancer of the larynx in the United States. *Arch Otolaryngol Head Neck Surg* 1997;123:475-483.
- Mendenhall WM, Parsons JT, Stringer SP, et al: The role of radiation therapy in laryngeal cancer. *CA Cancer J Clin* 1990;40:150-165.
- The Department of Veterans Affairs Laryngeal Cancer Study Group: Induction chemotherapy plus radiation compared with surgery plus radiation in patients with advanced laryngeal cancer. *N Engl J Med* 1991;324:1685-1690.
- Jacobs C, Goffinet DR, Goffinet L, et al: Chemotherapy as a substitute for surgery in the treatment of advanced resectable head and neck cancer: A report from the Northern California Oncology Group. *Cancer* 1987;60:1178-1183.
- Demard F, Chauvel P, Santini J, et al: Response to chemotherapy as justification for modification of the therapeutic strategy for pharyngolaryngeal carcinomas. *Head Neck* 1990;12:225-231.
- Pfister DG, Strong E, Harrison L, et al: Larynx preservation with combined chemotherapy and radiation therapy in advanced but resectable head and neck cancer. *J Clin Oncol* 1991;9:850-859.
- Karp DD, Vaughan CW, Carter R, et al: Larynx preservation using induction chemotherapy plus radiation therapy as an alternative to laryngectomy in advanced head and neck cancer: A long-term follow-up report. *Am J Clin Oncol* 1991;14:273-279.
- Urba SG, Forastiere AA, Wolf GT, et al: Intensive induction chemotherapy and radiation for organ preservation in patients with advanced resectable head and neck carcinoma. *J Clin Oncol* 1994;12:946-953.
- Clayman GL, Weber RS, Guillaumondegui O, et al: Laryngeal preservation for advanced laryngeal and hypopharyngeal cancers. *Arch Otolaryngol Head Neck Surg* 1995;121:219-223.
- Hong WK, Shapshay SM, Bhutani R, et al: Induction chemotherapy in advanced squamous head and neck carcinoma with high-dose cis-platinum and bleomycin infusion. *Cancer* 1979;44:19-25.
- Weaver A, Flemming S, Kish, J, et al: Cis-platinum and 5-fluorouracil as induction therapy for advanced head and neck cancer. *Am J Surg* 1982;144:445-448.
- Myers EN, Alvi A: Management of carcinoma of the supraglottic larynx: Evolution, current concepts, and future trends. *Laryngoscope* 1996;106:559-567.
- Levendag P, Sessions R, Vikram B, et al: The problem of neck relapse in early stage supraglottic larynx cancer. *Cancer* 1989;63:345-348.
- Fleming ID, Cooper JS, Henson DE, et al (eds): *Manual for Staging of Cancer*, ed 5. Philadelphia, Lippincott-Raven Publishers, 1997.
- Nguyen TD, Malissard L, Theobald S, et al: Advanced carcinoma of the larynx: Results of surgery and radiotherapy without induction chemotherapy (1980-1985): A multivariate analysis. *Int J Radiat Oncol Biol Phys* 1996;36:1013-1018.
- Tucker HM: *The Larynx*, ed 2. New York, Thieme Medical Publishers, 1993.
- Gussenbauer C: Ueber die erst durch T. Billroth am menschen ausgefuhrte kehlkopf extirpation. *Arch Clin Chir* 1872;17:343.
- Gluck T: Die chirurgische therapie des kehlkopfkarcinoms. *Jahreskurse Arzt Fortbild* 1912;2:20-41.
- Coutard H: Roentgentherapie of epitheliomas of the tonsillar region, laryngopharynx and larynx from 1920 to 1926. *Am J Roentgenol* 1921;28:313-331.
- Kirchner JA, Som ML: Clinical and histological observations on supraglottic cancer. *Ann Otol Rhinol Laryngol* 1971;80:638-645.
- Alonso JM: Conservation surgery for cancer of the larynx. *Transactions of the American Academy of Ophthalmology* 1947;51:633-642.
- Ogura JH: Supraglottic subtotal laryngectomy and radical neck dissection for carcinoma of the

epiglottis. *Laryngoscope* 1958;68:983-1003.

25. Ogura JH, Session DG, Spector GJ: Conservation surgery for epidermoid carcinoma of the supraglottic larynx. *Laryngoscope* 1975;85:1808-1815.

26. Pearson BW: Subtotal laryngectomy. *Laryngoscope* 1981;91:1904-1912.

27. Laccourreye O, Salzer SJ, Brasnu D, et al: Glottic carcinoma with a fixed true vocal cord: Outcomes after neoadjuvant chemotherapy and supracricoid partial laryngectomy with cricothyroid-epiglottopexy. *Otolaryngol Head Neck Surg* 1996;114:400-406.

28. Jako GJ: Laser surgery of the vocal cords: An experimental study with carbon dioxide lasers on dogs. *Laryngoscope* 1972;82:2204-2216.

29. Steiner W: Experience in endoscopic laser surgery of malignant tumours of the upper aero-digestive tract. *Adv Otorhinolaryngol* 1988;39:135-144.

30. Zeitels SM, Vaughan CW, Domanowski GF: Endoscopic management of early supraglottic cancer. *Ann Otol Rhinol Laryngol* 1990;99:951-956.

31. Singer MI, Blom ED, Hamaker RC: Further experience with voice restoration after total laryngectomy. *Ann Otol Rhinol Laryngol* 1981;90(5 Pt 1):498-502.

32. McNeil BJ, Weichselbaum R, Pauker SG: Speech and survival: Tradeoffs between quality and quantity of life in laryngeal cancer. *N Engl J Med* 1981;305:982-987.

33. DeSanto LW, Olsen KD, Perry WC, et al: Quality of life after surgical treatment of cancer of the larynx. *Ann Otol Rhinol Laryngol* 1995;104:763-769.

34. Harwood AR, Rawlinson E: The quality of life of patients following treatment for laryngeal cancer. *Int J Radiat Oncol Biol Phys* 1983;9:335-338.

35. Maas A: A model for quality of life after laryngectomy. *Soc Sci Med* 1991;33:1373-1377.

36. Shirinian MH, Weber RS, Lippman SM, et al: Laryngeal preservation by induction chemotherapy plus radiotherapy in locally advanced head and neck cancer: The M.D. Anderson Cancer Center experience. *Head Neck* 1994;16:39-44.

37. Hong WK, Lippman SM, Wolf GT: Recent advances in head and neck cancer-larynx preservation and cancer chemoprevention: The seventeenth annual Richard and Hinda Rosenthal Foundation award lecture. *Cancer Res* 1993;53:5113-5120.

38. Wolf GT, Hong WK: Induction chemotherapy for organ preservation in advanced laryngeal cancer: Is there a role? *Head Neck* 1995;17:279-283.

39. Kirchner JA, Owen JR: Five hundred cancers of the larynx and pyriform sinus: Results of treatment by radiation and surgery. *Laryngoscope* 1977;87:1288-1303.

40. Harwood AR, Hawkins NV, Beale FA, et al: Management of advanced glottic cancer: A 10 year review of the Toronto experience. *Int J Radiat Oncol Biol Phys* 1979;5:899-904.

41. Harwood AR, Beale FA, Cummings BJ, et al: Supraglottic laryngeal carcinoma: An analysis of dose-time-volume factors in 410 patients. *Int J Radiat Oncol Biol Phys* 1983;9:311-319.

42. Mendenhall WM, Parsons JT, Stringer SP, et al: Stage T3 squamous cell carcinoma of the glottic larynx: A comparison of laryngectomy and irradiation. *Int J Radiat Oncol Biol Phys* 1992;23:725-732.

43. Yuen A, Medina JE, Goepfert H, et al: Management of stage T3 and T4 glottic carcinomas. *Am J Surg* 1984;148:467-472.

44. Wendt TG, Grabenbauer GG, Rodel CM, et al: Simultaneous radiochemotherapy versus radiotherapy alone in advanced head and neck cancer: A randomized multicenter study. *J Clin Oncol* 1998;16:1318-1324.

45. Adelstein DJ, Saxton JP, Lavertu P, et al: A phase III randomized trial comparing concurrent chemotherapy and radiotherapy with radiotherapy alone in resectable stage III and IV squamous cell head and neck cancer: Preliminary results. *Head Neck* 1997;19:567-575.

46. Kraus DH, Pfister DG, Harrison LB, et al: Salvage laryngectomy for unsuccessful larynx preservation therapy. *Ann Otol Rhinol Laryngol* 1995;104:936-941.

47. Davidson J, Briant D, Gullane P, et al: The role of surgery following radiotherapy failure for advanced laryngopharyngeal cancer: A prospective study. *Arch Otolaryngol Head Neck Surg* 1994;120:269-276.

48. Sessler AM, Esclamado RM, Wolf GT: Surgery after organ preservation therapy: Analysis of wound complications. *Arch Otolaryngol Head Neck Surgery* 1995;121:162-165.

49. Wolf GT, Fisher SG: Effectiveness of salvage neck dissection for advanced regional metastases when induction chemotherapy and radiation are used for organ preservation. *Laryngoscope* 1992;102:934-949.

50. Armstrong J, Pfister D, Strong E, et al: The management of the clinically positive neck as part of a larynx preservation approach. *Int J Radiat Oncol Biol Phys* 1993;26:759-765.

51. Withers HR, Taylor JM, Maciejewski B: The hazard of accelerated tumor clonogen repopulation during radiotherapy. *Acta Oncol* 1988;27:131-146.

52. Bourhis J, Wilson G, Wilbaut P, et al: Rapid tumor cell proliferation after induction chemotherapy in oropharyngeal cancer. *Laryngoscope* 1994;104:468-472.

53. Fowler JF, Lindstrom M: Loss of local control with prolongation in radiotherapy. *Int J Radiat Oncol Biol Phys* 1992;23:457-467.

54. Wang CC, Blitzer PH, Suit HD: Twice-a-day radiation therapy for cancer of the head and neck. *Cancer* 1985;55(Suppl 9):2100-2104.

55. Eisbruch A, Thornton AF, Urba S, et al: Chemotherapy followed by accelerated fractionated radiation for larynx preservation in patients with advanced laryngeal cancer. *J Clin Oncol* 1996;14:2322-2330.

56. Adelstein DJ, Saxton JP, Van Kirk MA, et al: Continuous course radiation therapy and concurrent combination chemotherapy for squamous cell head and neck cancer. *Am J Clin Oncol* 1994;17:369-373.

57. Glicksman AS, Wanebo H, Slotman G, et al: Concurrent platinum based chemotherapy and hyperfractionated accelerated radiotherapy with late intensification in advanced head and neck cancer. Presented at the Fourth International Conference on Head and Neck Cancer; July 29, 1996; Toronto, Canada.
58. Pfister D, Harrison L, Kraus D, et al: Larynx preservation: Does induction cisplatin-based chemotherapy compromise the delivery of concomitant chemotherapy with radiation therapy? Proceedings of the American Society of Clinical Oncology 1994;13:292. Abstract.
59. Pfister DG, Armstrong J, Strong E, et al: A matched-pair analysis of cisplatin/5-fluorouracil versus other cisplatin-based regimens as induction chemotherapy for larynx preservation treatment. Proceedings of the American Society of Clinical Oncology 1993;12:280. Abstract.
60. Pfister DG, Bajorin D, Motzer R, et al: Cisplatin, fluorouracil and leucovorin: Increased toxicity without improved response in squamous cell head and neck cancer. Arch Otolaryngol Head Neck Surg 1994;120:89-95.
61. Vokes EE, Weichselbaum RR, Mick R, et al: Favorable long-term survival following induction chemotherapy with cisplatin, fluorouracil, and leucovorin and concomitant chemoradiotherapy for locally advanced head and neck cancer. J Natl Cancer Inst 1992;84:877-882.
62. Clark JR, Busse PM, Norris CM Jr, et al: Induction chemotherapy with cisplatin, fluorouracil, and high-dose leucovorin for squamous cell carcinoma of the head and neck: Long-term results. J Clin Oncol 1997;15:3100-3110.
63. Shin DM, Glisson BS, Khuri FR, et al: Phase II trial of paclitaxel, ifosfamide, and cisplatin in patients with recurrent head and neck squamous cell carcinoma. J Clin Oncol 1998;16:1325-1330.
64. Robbins KT, Fontanesi J, Wong FS, et al: A novel organ preservation protocol for advanced carcinoma of the larynx and pharynx. Arch Otolaryngol Head Neck Surg 1996;122:853-857.
65. Fu KK, Hammond E, Pajak TF, et al: Flow cytometric quantification of the proliferation-associated nuclear antigen p105 and DNA content in advanced head and neck cancer: Results of RTOG 91-08. Int J Radiation Oncol Biol Phys 1994;29:661-671.
66. Wolf GT, Fisher SG, Truelson JM, et al: DNA content and regional metastases in patients with advanced laryngeal squamous carcinoma. Department of Veterans Affairs Laryngeal Study Group. Laryngoscope 1994;104:479-483.
67. Corvo R, Giaretti W, Sanguineti G, et al: In vivo cell kinetics in head and neck squamous cell carcinomas predicts local control and helps guide radiotherapy regimen. J Clin Oncol 1995;13:1843-1850.
68. Bradford CR, Zhu S, Wolf GT, et al: Overexpression of p53 predicts organ preservation using induction chemotherapy and radiation in patients with advanced laryngeal cancer. Department of Veterans Affairs Laryngeal Cancer Study Group. Otolaryngol Head Neck Surg 1995;113:408-412.
69. Gregg CM, Beals TE, McClatchey KM, et al: DNA content and tumor response to induction chemotherapy in patients with advanced laryngeal squamous cell carcinoma. Otolaryngol Head Neck Surg 1993;108:731-737.
70. Tennvall J, Wennerberg J, Anderson H, et al: DNA analysis as a predictor of the outcome of induction chemotherapy in advanced head and neck carcinomas. Arch Otolaryngol Head Neck Surg 1993;119:867-870.
71. Truelson JM, Fisher SG, Beals TE, et al: DNA content and histologic growth pattern correlate with prognosis in patients with advanced squamous carcinoma of the larynx. Department of Veterans Affairs Cooperative Laryngeal Cancer Study Group. Cancer 1992;70:56-62.
72. Robbins KT, Connors KM, Storniolo AM, et al: Sponge-gel-supported histoculture drug-response assay for head and neck cancer: Correlations with clinical response to cisplatin. Arch Otolaryngol Head Neck Surg 1994;120:288-292.
73. Begg AC, Hofland I, Van Glabekke M, et al: Predictive value of potential doubling time for radiotherapy of head and neck tumor patients: Results from the EORTC cooperative trial 22851. Semin Radiat Oncol 1992;2:22-25.
74. Laramore GE: Cost analysis of chemoradiation: A basic approach and its application. Presented at the Fourth International Conference on Head and Neck Cancer; July 28, 1996; Toronto, Canada.
75. Lefebvre JL, Chevalier D, Luboinski B, et al: Larynx preservation in pyriform sinus cancer: Preliminary results of a European Organization for Research and Treatment of Cancer phase III trial: EORTC Head and Neck Cooperative Group. J Natl Cancer Inst 1996;88:890-899.
76. Beauvillain C, Mahe I, Bourdin S, et al: Final results of a randomized trial comparing chemotherapy plus radiotherapy with chemotherapy plus surgery plus radiotherapy in locally advanced resectable hypopharyngeal carcinomas. Laryngoscope 1997;107:648-653.
77. Kraus DH, Pfister DG, Harrison LB, et al: Larynx preservation with combined chemotherapy and radiation therapy in advanced hypopharynx cancer. Otolaryngol Head Neck Surg 1994;111:31-37.
78. Kraus DH, Zelefsky MJ, Brock HA, et al: Combined surgery and radiation therapy for squamous cell carcinoma of the hypopharynx. Otolaryngol Head Neck Surg 1997;116:637-641.
79. Zelefsky MJ, Kraus DH, Pfister DG, et al: Combined chemotherapy and radiotherapy versus surgery and postoperative radiotherapy for advanced hypopharyngeal cancer. Head Neck 1996;18:405-411.
80. Lazarus CL, Logemann JA, Pauloski BR, et al: Swallowing disorders in head and neck cancer patients treated with radiotherapy and adjuvant chemotherapy. Laryngoscope 1996;106:1157-1166.